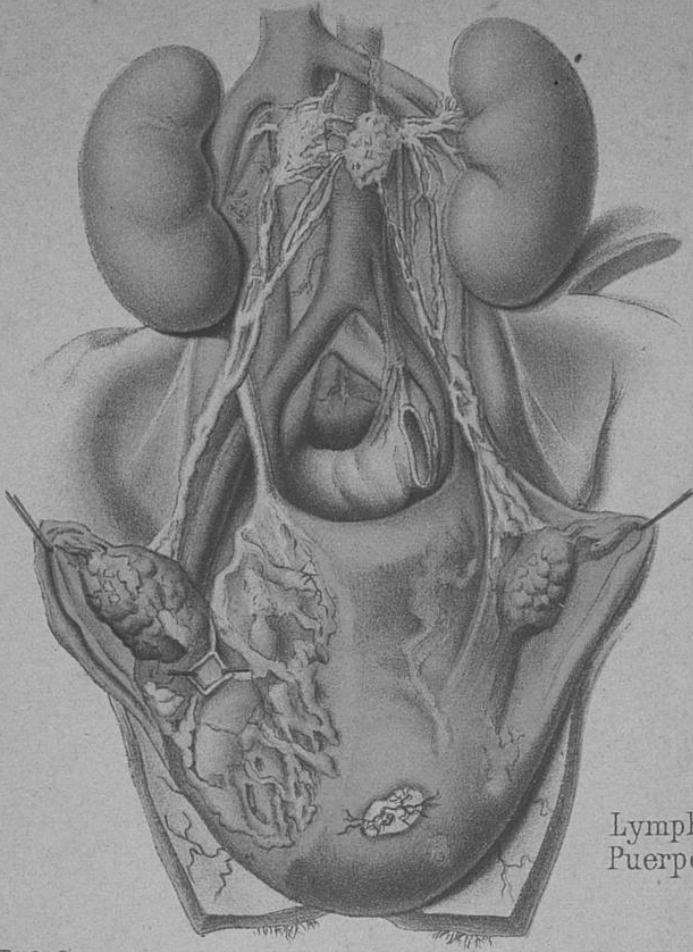

Lymphangitis beim Puerperalfieber.

Fig. 2.

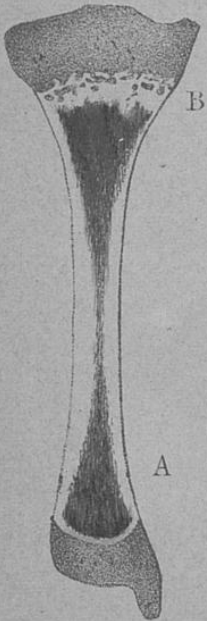
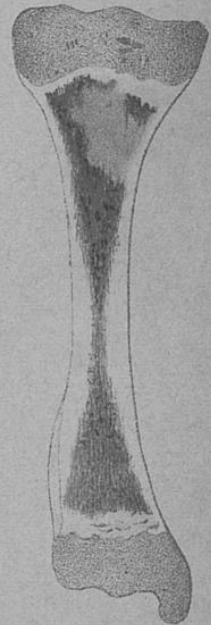


Fig. 3.



Fig. 4.



Osteochondritis syphilitica.





